



Prescription Profile of Anti-inflammatory Drugs After Excision Biopsy of Oral Soft Tissue Disease in Palembang

Kemas Muhammad Deky Berryl Ananta Putra¹, Siti Rusdiana Puspa Dewi^{1*}, Nita Parisa²

¹Dentistry Study Program, Faculty of Medicine, Universitas Sriwijaya, Palembang, Indonesia

²Department of Pharmacology, Faculty of Medicine, Universitas Sriwijaya, Palembang, Indonesia

*Correspondence author email: sitirusdiana@fk.unsri.ac.id

Abstract

Introduction: Oral soft tissue lesion is an abnormal condition of the oral soft tissue. Clinically this lesion can be seen from the changes of colour and size in the surface of the oral soft tissues. There are various types of lesions in the oral cavity, including primary and secondary lesions. The treatment of each lesion is also different, it can be with non-surgical treatment, or surgical treatment. Biopsy is a surgical treatment procedure where tissue is taken for histopathological examination. The purpose of biopsy is to help establish a diagnosis and determine the prognosis of a treatment. After an excisional biopsy, dentists usually give patients anti-inflammatory as a pain control. Anti-inflammatory drugs divide into two groups, steroid and non-steroidal drugs. The most commonly used are non-steroidal groups. The use of anti-inflammatory drugs is seen based on the best therapeutic effects and the fewest side effects. **Purpose:** The purpose of this study was to examine the prescription profile of anti-inflammatory drugs after excision biopsy of soft tissue disease performed by dentists in Palembang. **Method:** This research was a descriptive study with survey technique. This research was conducted at the dentist's practice and the hospital's dental clinic in Palembang. Data was collected using a questionnaire form which was filled in by the respondents themselves. The questionnaire consists of several questions that were considered representative to find out how the prescription profile of anti-inflammatory use after excision biopsy of oral soft tissue disease by dentists and or specialist in Palembang. **Results:** The results of the study showed that the frequency distribution of anti-inflammatory drugs used by dentists in Palembang after excision biopsy was diclofenac (52.5%) and tablet preparations are the main choice (92.5%). **Conclusion:** The most widely used prescription of anti-inflammatory drugs after excision biopsy of oral soft tissue disease by dentists in Palembang was diclofenac, and tablet preparation of anti-inflammatory drugs was most prescribed by dentist in Palembang.

Keywords: Biopsy; dentist; diclofenac; oral lesion

Introduction

Oral soft tissue lesion is an abnormal condition of the oral soft tissue.¹ Clinically this lesion can be seen from the changes of colour and size in the surface of the oral soft tissues.² There are various types of lesions in the oral cavity, including primary and secondary lesions. The primary lesion is the first lesion to appear which if not treated immediately, changes will occur and secondary lesions will form. Primary lesions include vesicles, bullae, macules, pustules and others.³ Secondary lesions include erosions, ulcers, fissures, and others. Red lesions and white lesions are also lesions that can be found in the soft tissues of the oral cavity based on the discoloration of the lesions.⁴ The treatment of each lesion is also different, it can be with non-surgical treatment, or surgical treatment. Some examples of lesions in the soft tissues of the oral cavity are mucoceles and traumatic fibromas.⁵ Department of Diagnostic



Sciences, Kuwait University, reviewed that traumatic mucoceles and fibromas are the two most common oral soft tissue lesions.⁶

Biopsy is a surgical treatment procedure where tissue is taken for histopathological examination.⁷ The purpose of biopsy is to help establish a diagnosis and determine the prognosis of a treatment. One of the most frequently performed biopsy techniques in the Department of Oral Medicine is excisional biopsy.⁸ Excisional biopsy is a medical procedure with perform the removal of all abnormal tissue along with the surrounding healthy tissue.⁹

After an excisional biopsy, dentists usually give patients anti-inflammatory as a pain control.¹⁰ Anti-inflammatory drugs divide into two groups, steroid and non-steroidal drugs.¹¹ The most commonly used are non-steroidal groups. Non-steroidal anti-inflammatory drugs include many kinds, such as ibuprofen, diclofenac, phenylbutazone, mefenamic acid, naproxen, fenoprofen, and flurbiprofen. For steroid anti-inflammatory drugs, corticosteroids can be used, such as hydrocortisone, dexamethasone, prednisone, betamethasone and methylprednisolone.¹² The use of anti-inflammatory drugs is seen based on the best therapeutic effects and the fewest side effects.¹⁰ Steroid drugs are used less frequently because they have greater side effects.¹³ Oral administration of drugs is more often used in dentistry because the patient is fully conscious or *compos mentis*. Based on the description above, we were interested in examining the prescription profile of anti-inflammatory drugs after excision biopsy of soft tissue disease performed by dentists in Palembang.

Methods

This research was a descriptive study with survey technique. This research was conducted at the dentist's practice and the hospital's dental clinic in Palembang. The population in this study were general dentists and/or dental specialists in Palembang. The sample of this research was selected using purposive sampling technique. The sample size in this study was calculated using the formula from Lemeshow *et al* and obtained the number of samples in this study was 40 people. The inclusion criteria in this study were dentists and/or dental specialist who had performed excisional biopsies. Meanwhile, the exclusion criteria were dentists and/or specialist who were not willing to fill out the questionnaire form. Data was collected using a questionnaire form which was filled in by the respondents themselves. The questionnaire consists of several questions that were considered representative to find out how the prescription profile of anti-inflammatory use after excision biopsy of oral soft tissue disease by dentists and or specialist in Palembang. The data obtained from the completed questionnaires were collected, processed, and analyzed simply using Microsoft Excel and then presented in the form of a frequency distribution chart to determine the frequency of respondents' answers.

Results

The results of the study showed that the frequency distribution of anti-inflammatory drugs used by dentists in Palembang after excision biopsy was 52.5% diclofenac, 35% mefenamic acid, 7.5% dexamethason and the most rarely prescribed was ibuprofen (5%). (Chart 1)

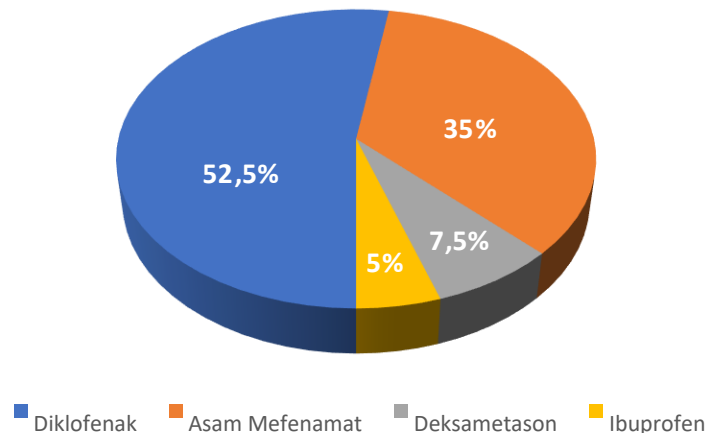


Chart 1. The frequency distribution of anti-inflammatory drugs

This study also showed that tablet preparations are the main choice for dentists in Palembang after excision biopsy of oral soft tissue disease (92.5%), while 2.5% of samples chose capsules, pulveres, caplets and 0% of dentists chose injection preparations. (Chart 2)

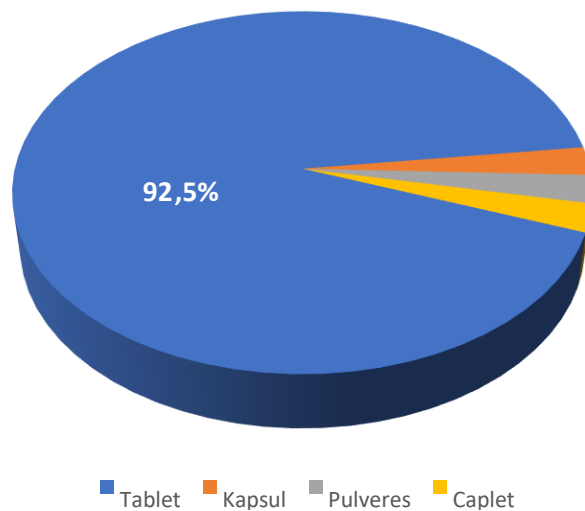


Chart 2. The frequency distribution of drug's preparation



Discussion

The aim of giving anti-inflammatory drugs was to reduce inflammatory symptoms after a excisional biopsy. The type of anti-inflammatory drug that was widely prescribed by dentists in Palembang is diclofenac. Datta reported that most implantologists in India prescribe anti-inflammatory drugs in the form of diclofenac and ibuprofen. Diclofenac is a type of non-steroidal anti-inflammatory drug that has been widely prescribed by dentists in various countries for a long time.¹⁴ Gazal and Al-Samadani reported that diclofenac potassium was effective in reducing pain after tooth extraction and cavity preparation compared with paracetamol and ibuprofen.¹⁵

Diclofenac potassium was preferred because this drug was easier to obtain, had a strong anti-inflammatory effect and had mild side effects. Diclofenac potassium was a non-steroidal anti-inflammatory drug that works by inhibiting the cyclooxygenase and lipoxygenase enzymes, interfering with the release of arachidonic acid, inhibiting the synthesis of prostanoids (such as prostaglandins, prostacyclin, thromboxane).¹⁶ Prostaglandins were a type of prostanoid as mediators of pain in inflammation.¹⁷

Besides potassium diclofenac, dentists in Palembang also prescribe mefenamic acid. It was because mefenamic acid was a type of anti-inflammatory generally available in public health services, such as in hospitals or in pharmacies in Palembang. Mefenamic acid also had a strong anti-inflammatory effect that suppresses the production of prostaglandins, so that pain due to inflammation could be reduced.¹⁸ Moll *et al* said that dentists in several cities in America prescribe a lot of single-dose mefenamic acid after surgery such as tooth extraction.¹⁹ Pozzi and Gallelli reported that the anti-pain effect of mefenamic acid is equivalent to that of ibuprofen in dental treatment.²⁰ Other studies have shown that mefenamic acid is effective in reducing inflammatory pain, but not as strong as that of diclofenac.²¹

Anti-inflammatory drugs with tablet preparations were most often used by dentists in Palembang and were given to patients after excision biopsy. The choice of tablet as drug preparation was because people were more familiar with and widely available on the market. The patient's comfort level was also maintained by giving the tablet type of drug because the application of the drug was also easy. The patient could immediately consume the tablet orally.²²

Conclusion

The most widely used prescription of anti-inflammatory drugs after excision biopsy of oral soft tissue disease by dentists in Palembang was diclofenac, followed by mefenamic acid, dexamethason, and ibuprofen. Tablet preparation of anti-inflammatory drugs was most prescribed by dentist in Palembang.



References

1. Nikitakis N. Oral soft tissue lesions: A guide to differential diagnosis Part II: Surface alterations. *Braz J Oral Sci.* 2005 March 7;4(13):707-15
2. Goyal S, Shetty A, Singla I, Singla S, Verma A. Injuries to oral soft tissues by different factors: A clinical study. *Indian J Multidiscip Dent.* 2016 July 23;6(1):7-10
3. Logan. RM, Goss. AN. Biopsy of the oral mucosa and use of histopathology services. *Australian Dental Journal* 2010;55:(1 Suppl): 9–13.
4. Catherine M, Flaitz, Coleman GC. Differential Diagnosis of Oral Enlargement in Children. *American Academy of Pediatric Dentistry* 1995;17(4):295-300
5. Valerio RA, Queiroz AMD, Romualdo PC, Brentegani LG, Wanderley F. Mucocele and Fibroma : Treatment and Clinical Features For Differential Diagnosis. *Brazilian Dental Journal* 2013;24(5):537-41
6. Ali M, Joseph B, Sundaram D. Prevalence of Oral Mucosal Lesions in Patients of the Kuwait University Dental Center. *The Saudi Dental Journal* 2013 June;13(25):111-8
7. Vyas T. Biopsy of Oral Lesion – A Review Article. *J Adv Med Dent Scie Res.* 2018 January;6(1):27-35
8. Garibay CF, Nieves A, Leonardo B, Cosme G. Prevalence of biopsied oral lesions in a Department of Oral Surgery. *J Clin Exp Dent.* 2011;3(2):e73-7
9. Kumaraswamy KL, Vidhya M, Rao PK, Mukunda A. Oral biopsy: oral pathologist's perspective. *J Cancer Res Ther.* 2012; 8(2):192-198
10. Navadi N, Salehi A, Zarei M, Borna R. Pain Experience After Oral Mucosal Biopsy: A Quasi-experimental Study. *J Oral Health Epidemiol.* 2012;1(2):87-92
11. Onufrak NJ, Forrest A, Gonzales D. Pharmacokinetic and Pharmacodynamic Principles of Anti-Infective Dosing. *Clin Rher.* 2016; 38(9): 1930-1947
12. Alshakka M, Badullah W, Alolayan S, Mahmoud M. Prescribing Patterns of Non-steroidal Anti-inflammatory Drugs (NSAID) at Outpatient Departments of Four Hospitals. *Biomed Res.* 2018; 29(19): 3643-3647
13. Vijayalaxmi, Male P, Patil N, Maste M. Review: Steroids in Oral Mucosal Lesions. *IOSR Journal of Dental and Medical Sciences* 2016;15(3):35-9
14. Datta R, Grewal Y, Bath JS, Singh A. A survey of analgesic and anti-inflammatory drug prescription for oral implant surgery. *Plast Aesthet Res.* 2015; 2: 51-55
15. Gazal G, Al-Samadani KH. Comparison of paracetamol, ibuprofen, and diclofenac potassium for pain relief following dental extractions and deep cavity preparations. *Saudi Med J.* 2017; 38(3): 284-291
16. Altman R, Bosch B, Brune K, Patrignani P, Young C. Advances in NSAID development: evolution of diclofenac products using pharmaceutical technology. *Drugs* 2015; 75(8): 859-877
17. Onufrak NJ, Forrest A, Gonzales D. Pharmacokinetic and Pharmacodynamic Principles of Anti-Infective Dosing. *Clin Rher.* 2016; 38(9): 1930-1947
18. Abbas N, Oswald IDH, Pulhan CR. Accessing mefenamic acid form II through high-pressure recrystallisation. *Pharmaceutics* 2017; 9(6): 1-11
19. Moll R, Derry S, Moore RA, McQuay HJ. Single dose oral mefenamic acid for acute postoperative pain in adults. *Cochrane Database Syst Rev.* 2011; 2011(3): CD007553
20. Pozzi A, Gallelli L. Pain management for dentists: the role of ibuprofen. *Ann Stomatol (Roma).* 2011; 2 (3-4): 3-24
21. Kumar S, Tekur U, Singh B, Kumar D. Mefenamic acid and diclofenac in treatment of menorrhagia and dysmenorrhea in dysfunctional uterine bleeding: a randomized comparative study. *Int J Basic Clin Pharmacolog.* 2018; 7(10): 1905-1911
22. Andriani D, Wijaya I, Utami W. Profil Peresepan Sediaan Kapsul Racikan di Apotek X di Surabaya. *Departemen Farmasi Komunitas Fakultas Farmasi Universitas Airlangga* 2014;1(2):41-4